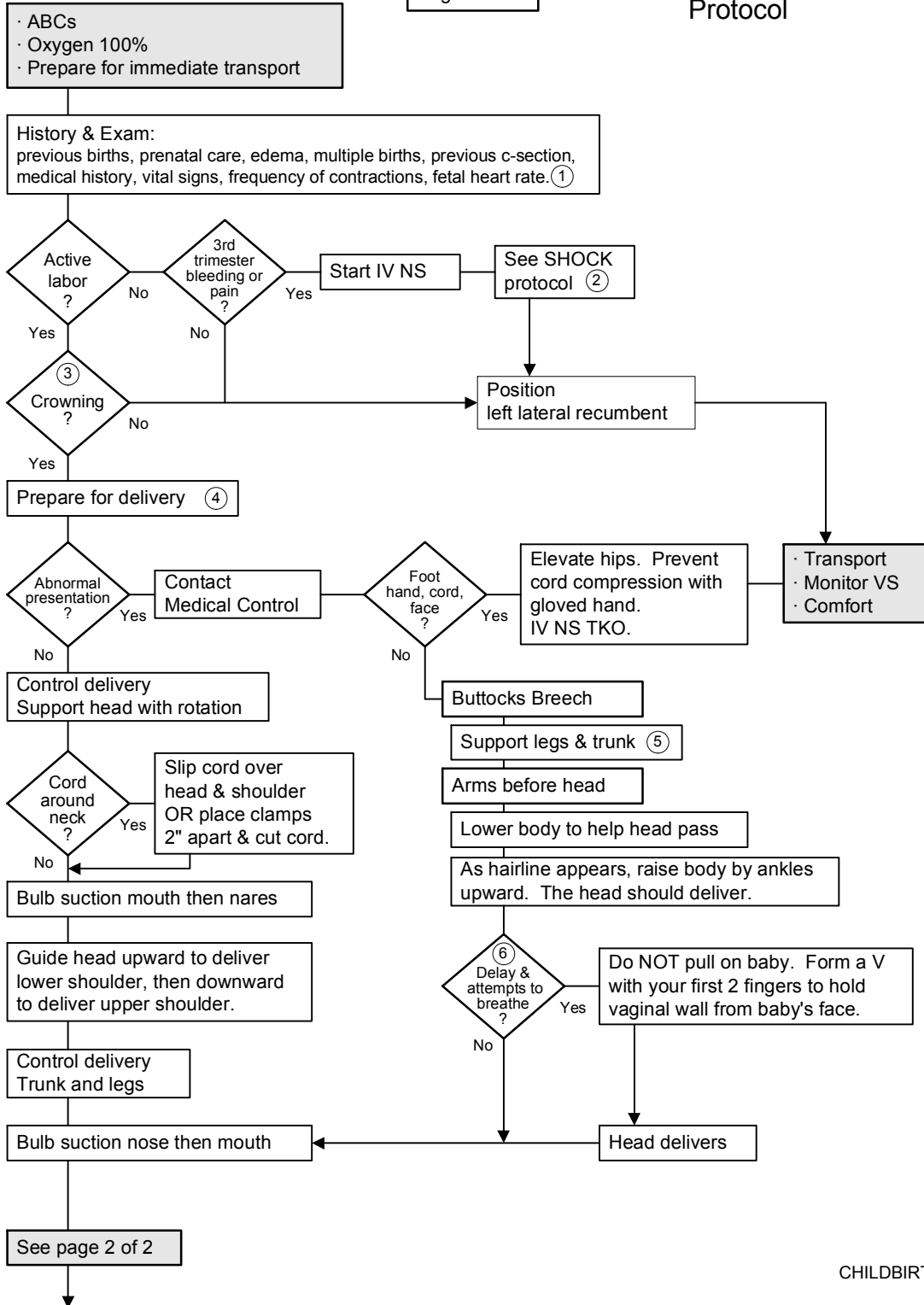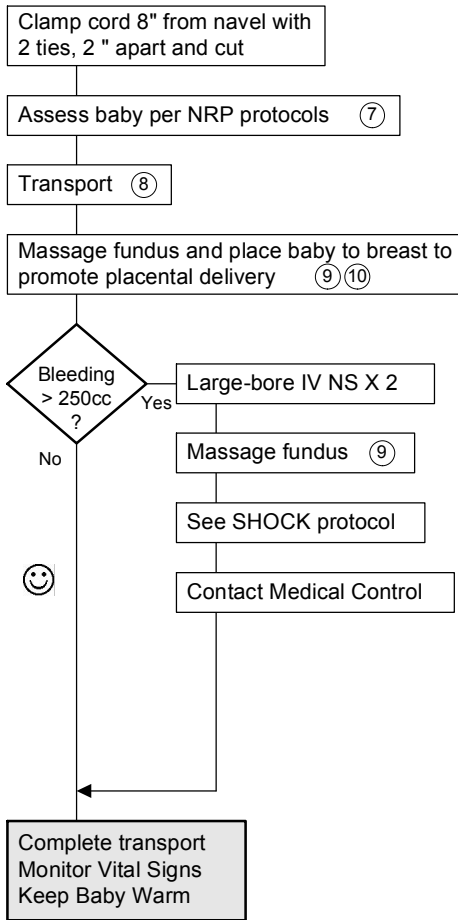


continued from page two



Apgar Score				
sign	0	1	2	
Heart rate	absent	<100	>100	
Respiratory effort	absent	slow	good, crying	
Muscle tone	limp	some flexion	active	
Reflex irritability	no response	grimace	cough/sneeze	
Color	blue, pale	body pink	completely pink	

- Document:
- Time of Birth
 - APGAR at 1 Min and 5 Min
 - Time of Placental Delivery
 - Estimated Fluid and Blood Loss
 - Complications if any
 - Care and Supportive Measures
 - Total IV Fluids Infused
 - Oxygen and Other Medications
 - Communication with Medical Control
 - Clinical Assessment and VS

- 1 Normal fetal heart rate = 120-150.
- 2 Do NOT perform a digital exam. Possible placental previa or abruption placenta.
- 3 Crowning may first appear during a contraction. Look for crowning between and during contractions. NO digital exams. Do NOT allow anyone to perform a digital exam.
- 4 Deliver baby on the scene ONLY if delivery is eminent.
- 5 Do NOT pull on baby.
- 6 If the babies head does not deliver and the baby begins to breath with its face pressed against the vaginal wall, place a gloved hand in the vagina with the palm toward the babies face. Form a "V" with the index and middle finger on either side of the infant's nose and push the vaginal wall away from the infant's face to allow unrestricted respiration.
- 7 Note exact time of birth.
- 8 Keep baby warm. Dry surface, cover head and protect from falls.
- 9 Massage fundus: gentle but firm, intermittent massage.
- 10 Do NOT pull on cord.

References:
 Bledsoe, Bryan: Paramedic Emergency Care. 32:965. 1994
 Caroline, Nancy: Emergency Care in the Streets. 35:775. 1991
 ECEMS, Effective 1/2008
 Copyright 2001-2008 East Cascade Emergency Medical Services