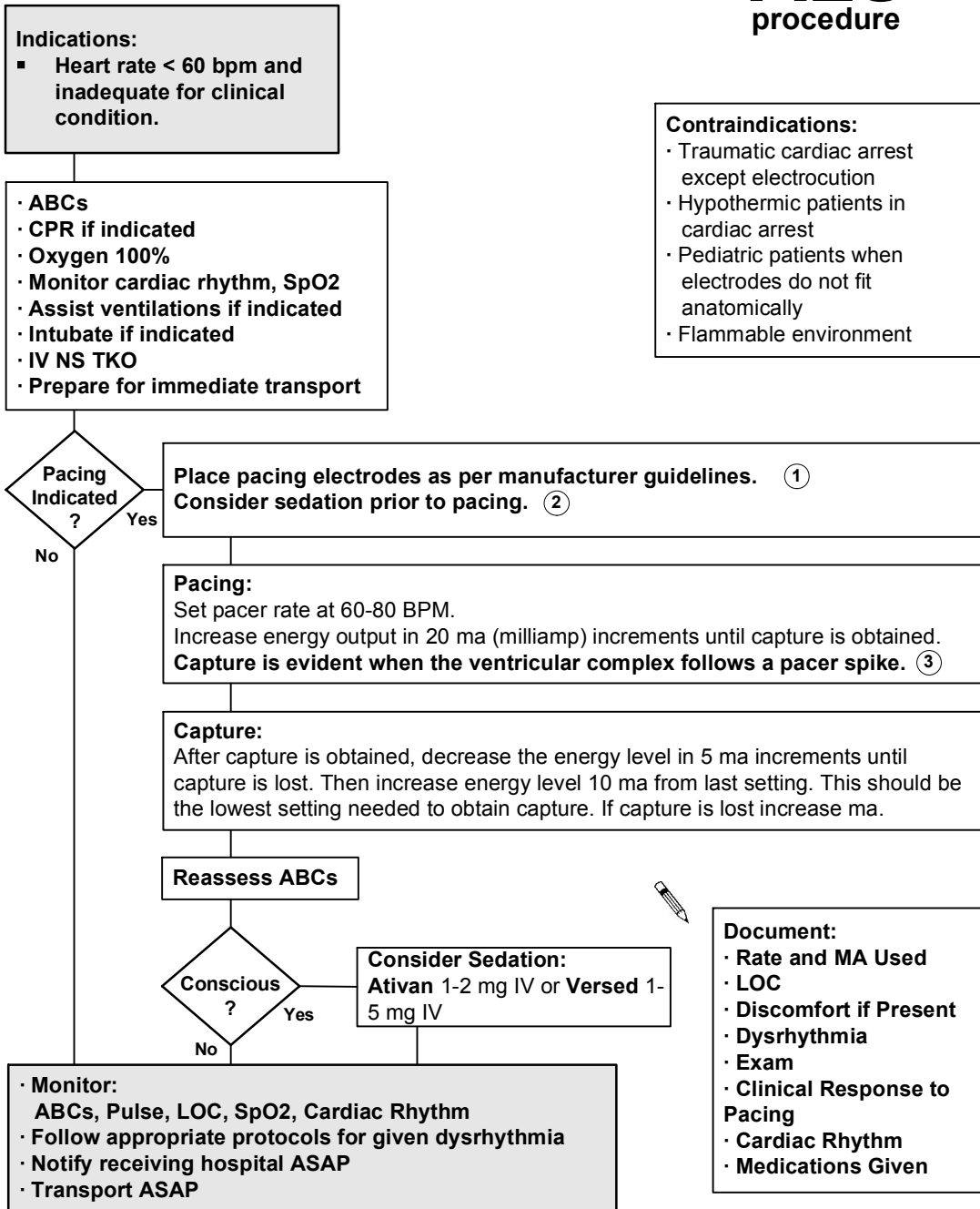


Cardiac Pacing: External

ALS procedure



1 Placement of electrodes should avoid breast tissue and large bony areas, such as the spine or sternum.

2 Sedation: Ativan 1-2 mg IV or Versed 1-5 mg IV titrate to effect

3 Electrical capture is evident when the ventricular complex consistently and immediately follows a pacer spike.

Mechanical capture is evident when a pulse is generated simultaneously with paced complexes.